



www.hublisuperspecialityhospital.com



24X7 Call Center # [7353-040-000](tel:7353-040-000)



HUBLI
SUPER SPECIALITY HOSPITAL



OncoIndia
Foundation

Centre of excellence for cancer care

Newsletter | Vol 3.Issue | 19 Jan 2023

An Initiative by
Hubli Super Speciality Hospital
India

Hubli Super Speciality Hospital Rambhapuri Kalyana Mantap Road,
Kalyannagar Vidyanagar Hubballi – 577-001, Karnataka, India



[/hublisuperspecialityhospital/](https://www.facebook.com/hublisuperspecialityhospital/)



24X7 Call Center # [7353-040-000](tel:7353-040-000)



www.hublisuperspecialityhospital.com



24X7 Call Center # [7353-040-000](tel:7353-040-000)



HUBLI
SUPER SPECIALITY HOSPITAL

A SINGLE SEPTOCUTANEOUS PERFORATOR BASED ANTEROLATERAL THIGH FREE FLAP RECONSTRUCTION FOR OROFACIAL DEFECT- A CASE REPORT

Introduction:

The anterolateral thigh flap is one of the fasciocutaneous flaps in the thigh based on the septocutaneous or musculocutaneous perforators derived from the lateral circumflex femoral system. The application of the anterolateral thigh flap as a favourable choice for head and neck reconstruction had been widely used in recent years mainly due to its minimal donor site morbidity. Repairing full-thickness cheek defects involving the oral commissure in the head and neck regions after tumor resection is a challenge for reconstructive surgeons. First, they are usually relatively large defects. Second, the axes of the cheek and intraoral lining are different from each other. Third, the shape and volume of the defect and the oral sphincter should be considered individually. We present our recent experience with the use of this versatile flap in full-thickness defects of the oral commissure.

Clinical History & Examination:

A 60 year old man presented with chief complaint of pain and burning sensation in the left side of face since last 4 months. On examination there was an ulceroproliferative lesion in the left buccal mucosa of size 4 x 3 cm inferiorly extending to the RMT region & superiorly extending to the oral commissure and involving the upper and lower lips. A biopsy was then performed which was reported as well differentiated squamous cell carcinoma. Clinically level I b lymph node was palpable, hard & tender. The clinical TNM staging of the patient was T4bN1MO.


Radiological Investigation and Treatment Planning:

CECT imaging revealed an ill defined heterogenous enhancing lesion in the left buccal mucosa extending to the Rmt and the Lower GBS with mandible erosion. Enlarged lymph node in level IB and II with greatest measuring 10 mmx 8 mm was noted. Based on the clinical and radiological examination the patient was planned for composite resection + Left MRND + ALT free flap reconstruction.

Hubli Super Speciality Hospital Rambhapuri Kalyana Mantap Road,
Kalyannagar Vidyanagar Hubballi – 577-001, Karnataka, India



[/hublisuperspecialityhospital/](https://www.facebook.com/hublisuperspecialityhospital/)



24X7 Call Center # [7353-040-000](tel:7353-040-000)



Treatment

A Wide local excision of the tumour with segmental mandibulectomy was done. A modified radical Neck dissection was performed on the left side. Facial Artery, Common facial vein and retro mandibular vein were surgically isolated for anastomosis. A left Alt free flap based on a single septocutaneous perforator was harvested. Anastomosis was done by using end to end anastomosis with facial artery and end to end anastomosis with common facial vein and retro mandibular vein. The flap inset was then done and the intraoral and extra oral defect was reconstructed.


Post operative course:

The patient underwent continuous flap monitoring in the post operative period. Pt received Inj clexane 0.4 BD and dextran infusion at the rate 50cc/hr for the first 3 days postoperatively. The patient had expected recovery during the post-operative period and was discharged with minimal grievances. The patient is yet to receive postoperative adjuvant radiotherapy.

Discussion:

The anterolateral thigh flap was originally described as a septocutaneous artery flap by Song et al. in 1984, the vascular variations of which were also reported by Koshima et al. in 1989. This flap usually has 87 % musculocutaneous perforator while 13 % septocutaneous perforator. As such, this flap has the ability to cover a variety of large cutaneous or mucosal defects. Donor site morbidity is limited. It is suitable for a two-team approach. In this manner, the duration of the operation can be reduced at least 1.5 to 2 hours.

In our case only one septocutaneous perforator derived from the lateral circumflex femoral artery were identified. The perforators were determined to lie within a circle with a radius of 3 cm. The center of this circle was the midpoint of the line marked between the anterosuperior iliac spine, the intermuscular septum, and the superolateral border of the patella.

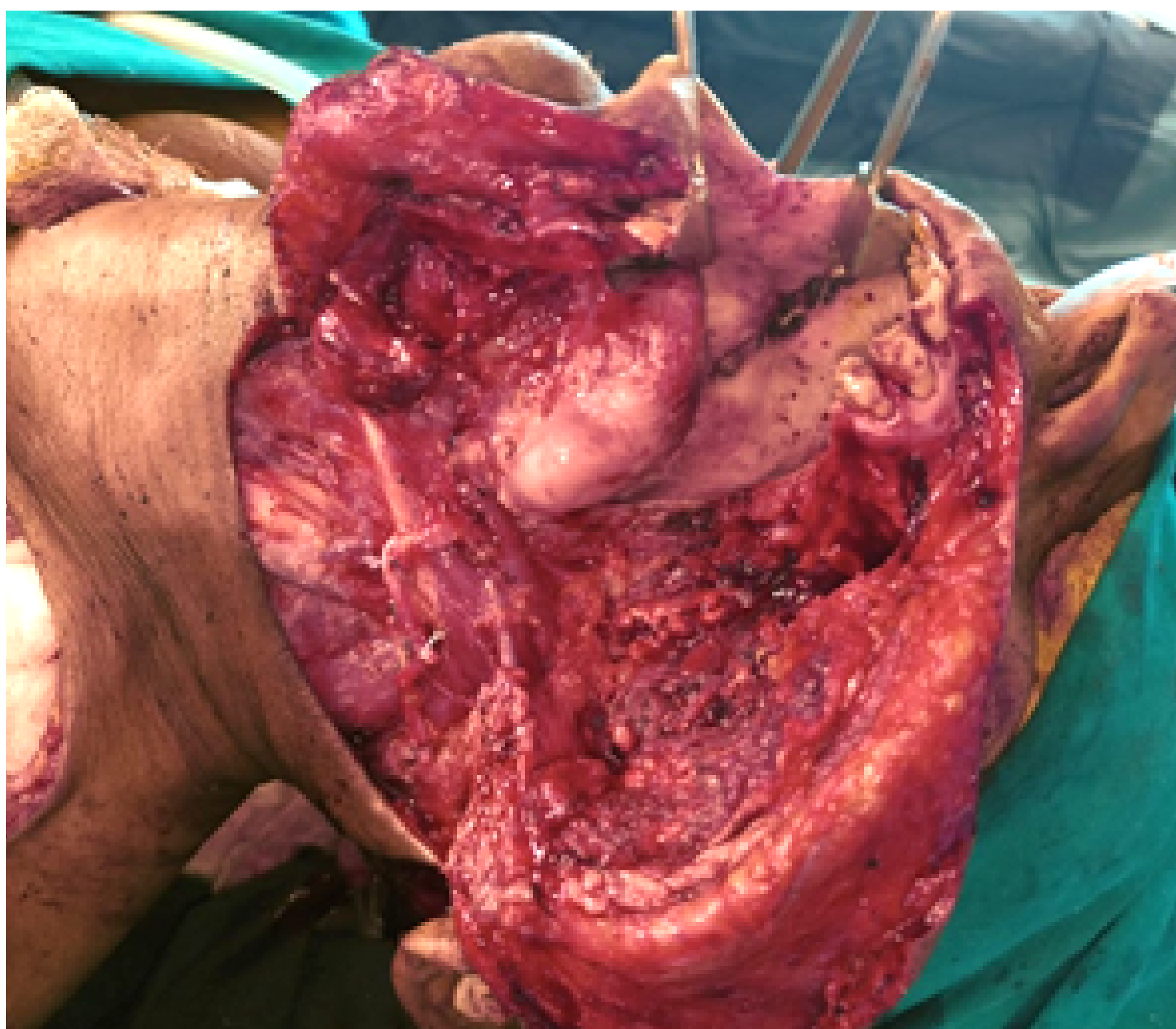




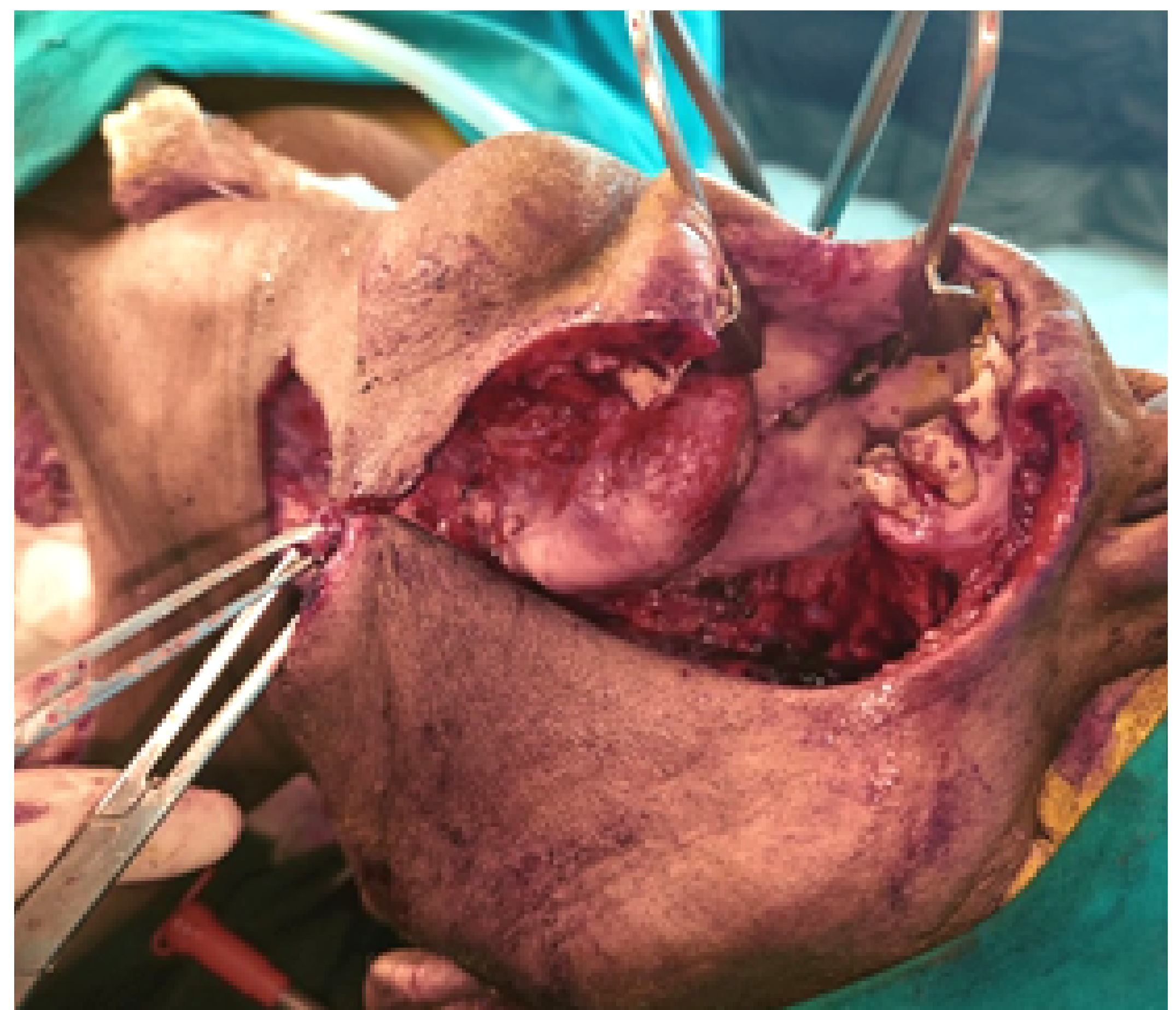
We think that the anterolateral thigh flap can be elevated without locating the perforators preoperatively with a hand-held Doppler probe if the flap includes the entire circle or a medial incision is made at least 3 cm from the midpoint of this line. We think that the variations in the vascular pedicle are not important for successful flap elevation if the possible variations are known by the surgeon, because the elevation of the flap is based on the "find-the-perforator and follow- it" principle in all circumstances. Retrograde dissection of the perforator to the main pedicle is accepted as a difficult and time-consuming procedure.

Conclusion:


As Alt free flap provides a large skin island it can be used for large defect reconstruction in head and neck surgeries. Perforator based dissection of this flap makes it one of the difficult flap for harvesting combined with meticulous requirement of anastomosis' of the vessels. But Because of its size, ease of harvest, vessel quality, and low donor site morbidity, the anterolateral thigh flap is aptly suited and has emerged the "workhorse" flap for soft tissue head and neck reconstruction.



**Fig 1: Wide local excision
of the tumour**



**Fig 2: Defect requiring
reconstruction**





www.hublisuperspecialityhospital.com



24X7 Call Center # 7353-040-000



HUBLI
SUPER SPECIALITY HOSPITAL

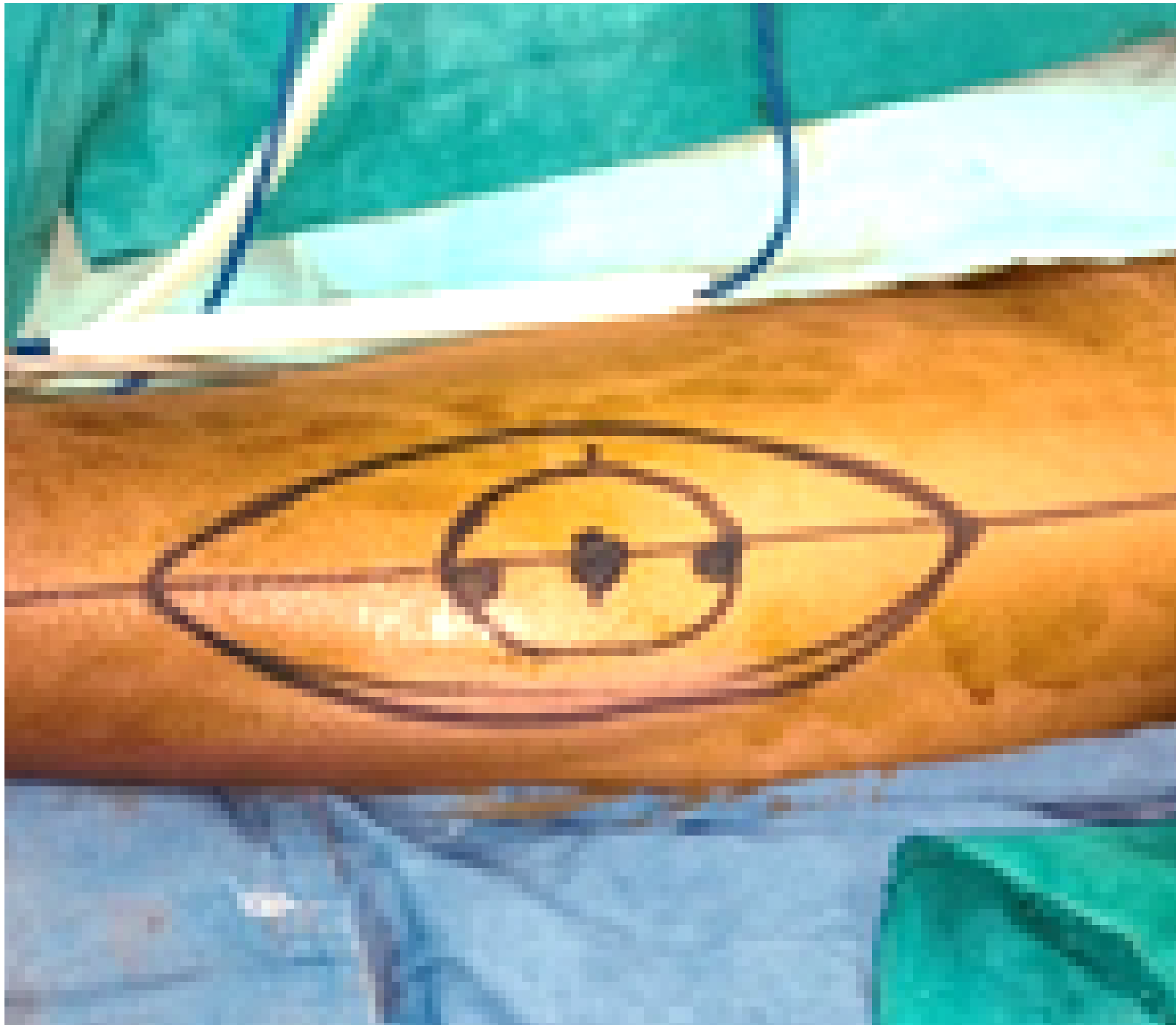

Fig 3: ALT Flap marking

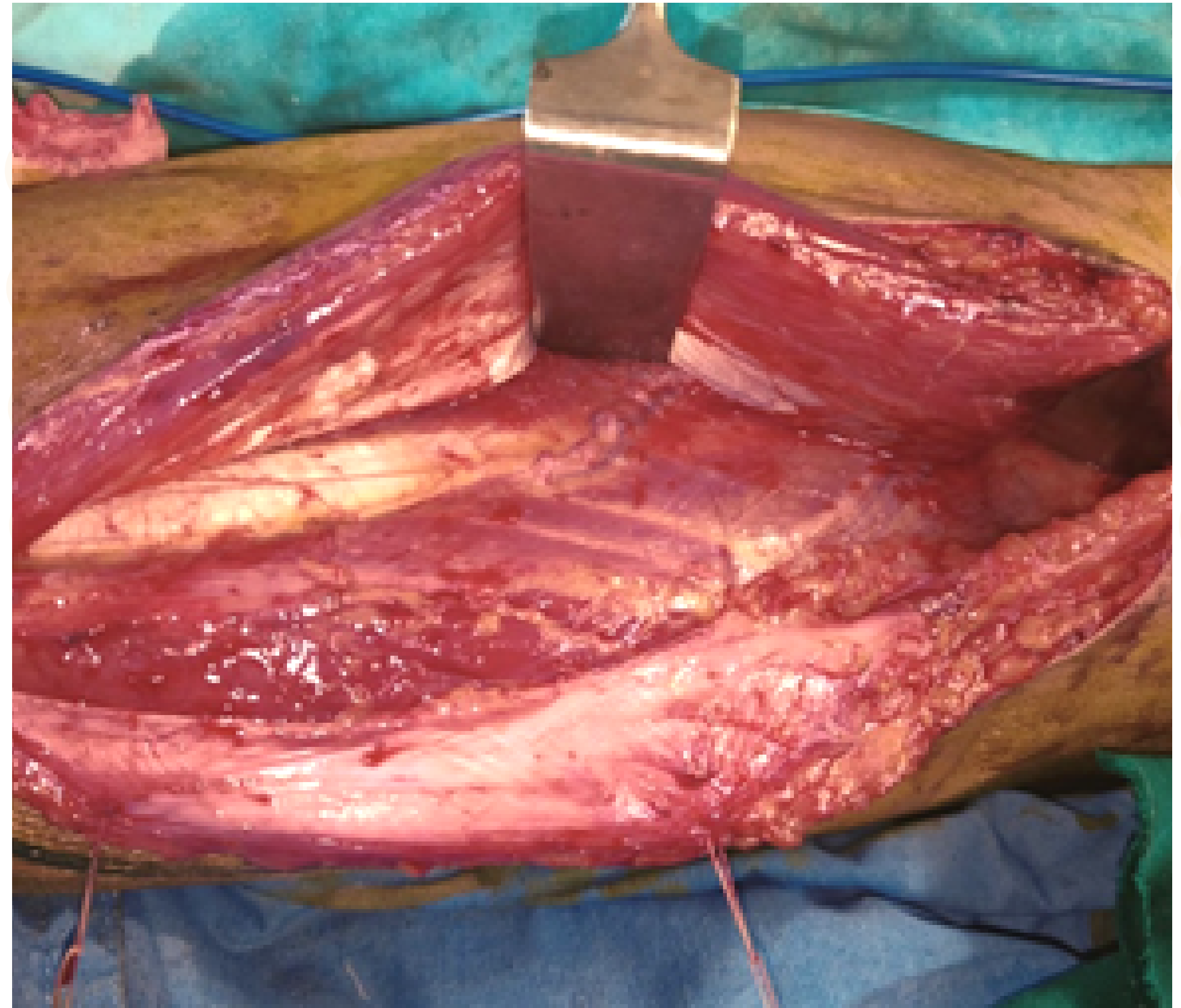


Fig 4: Flap elevation & Identification of main pedicle

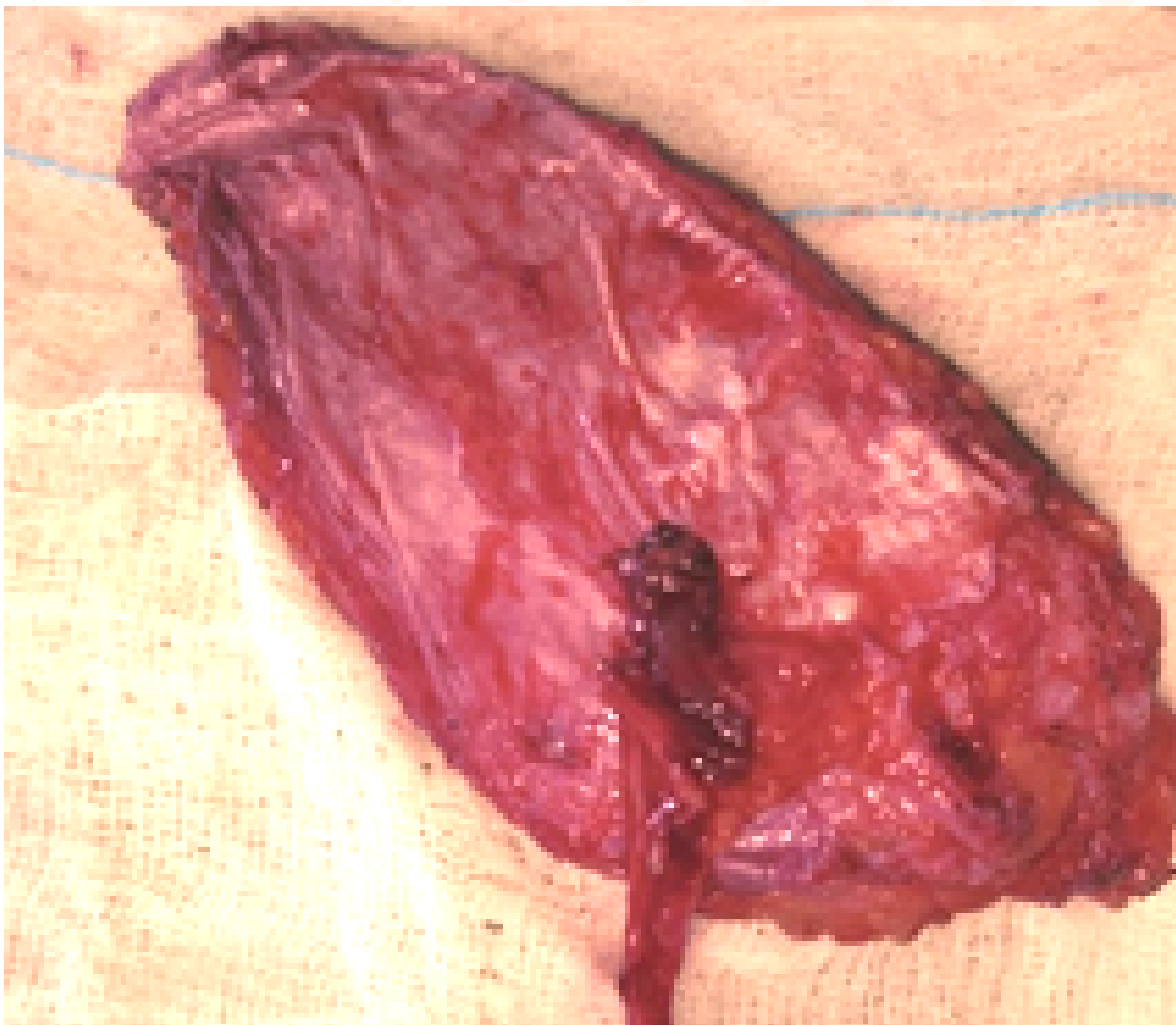


Fig 5: Single septocutaneous based ALT Flap harvest

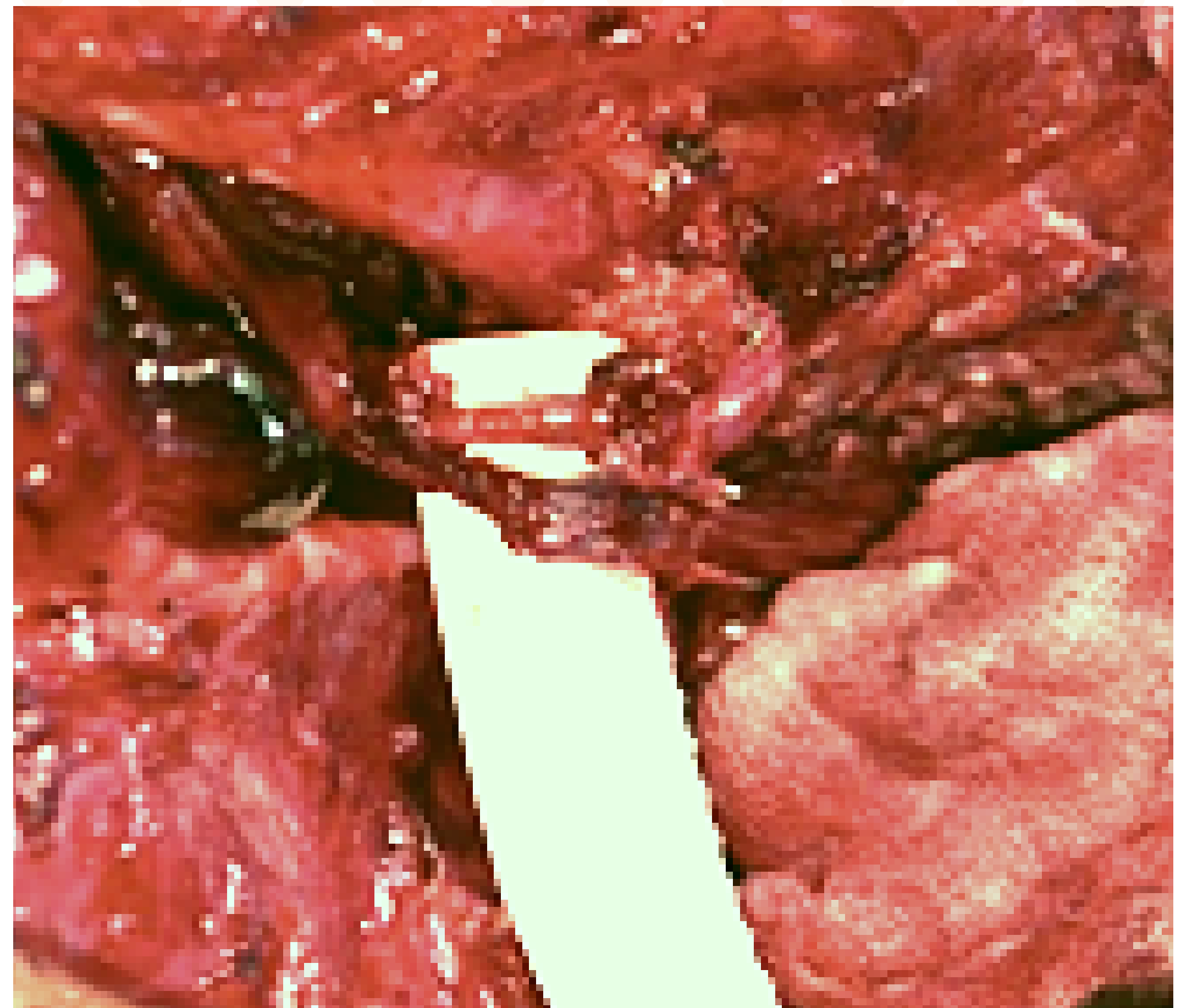



Fig 6: End to end anastomosis with facial artery and common facial vein

Hubli Super Speciality Hospital Rambhapuri Kalyana Mantap Road,
Kalyannagar Vidyanagar Hubballi – 577-001, Karnataka, India



[/hublisuperspecialityhospital/](https://www.facebook.com/hublisuperspecialityhospital/)



24X7 Call Center # 7353-040-000



www.hublisuperspecialityhospital.com



24X7 Call Center # 7353-040-000



HUBLI
SUPER SPECIALITY HOSPITAL



Fig 3: ALT Flap marking

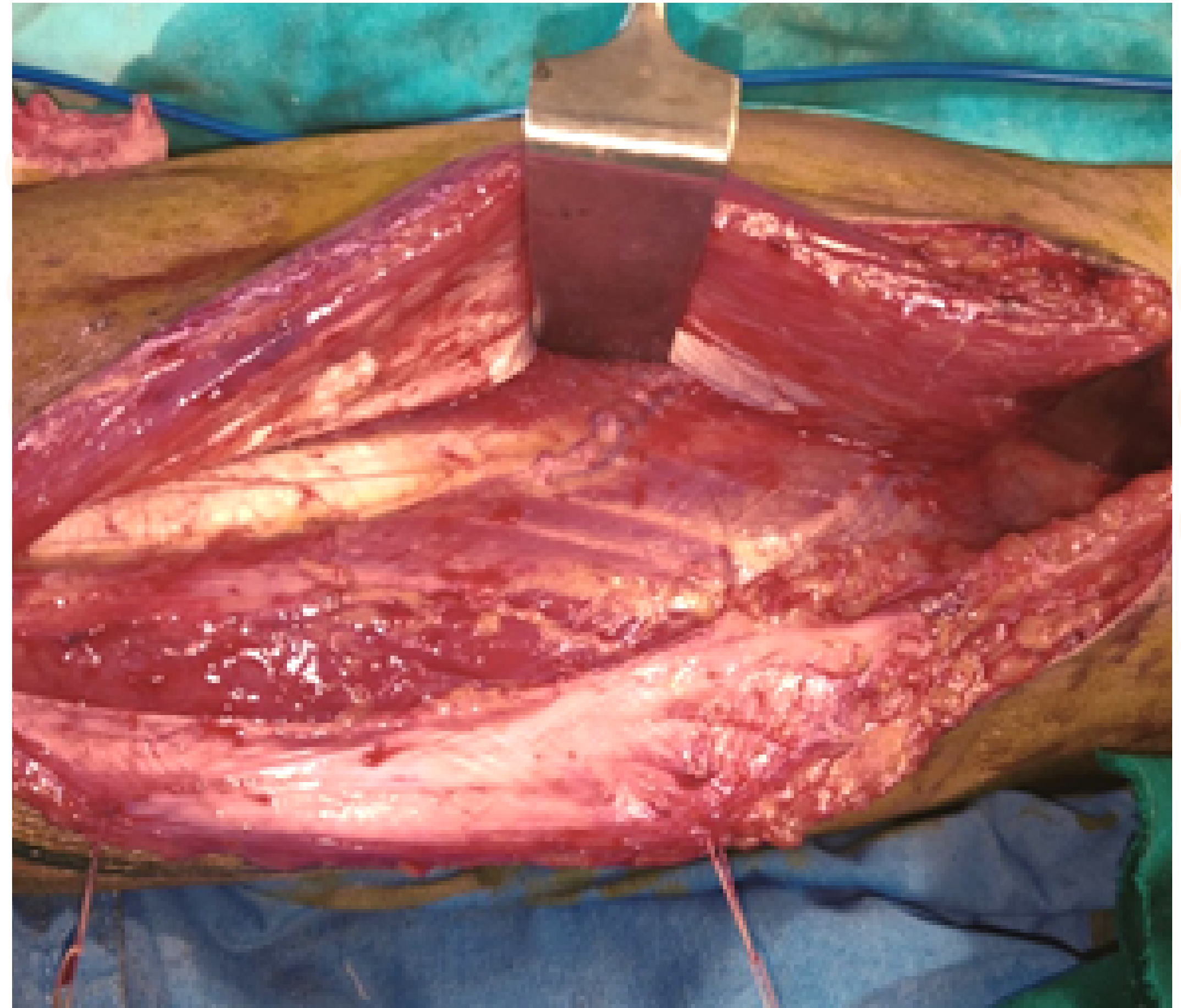


Fig 4: Flap elevation & Identification of main pedicle

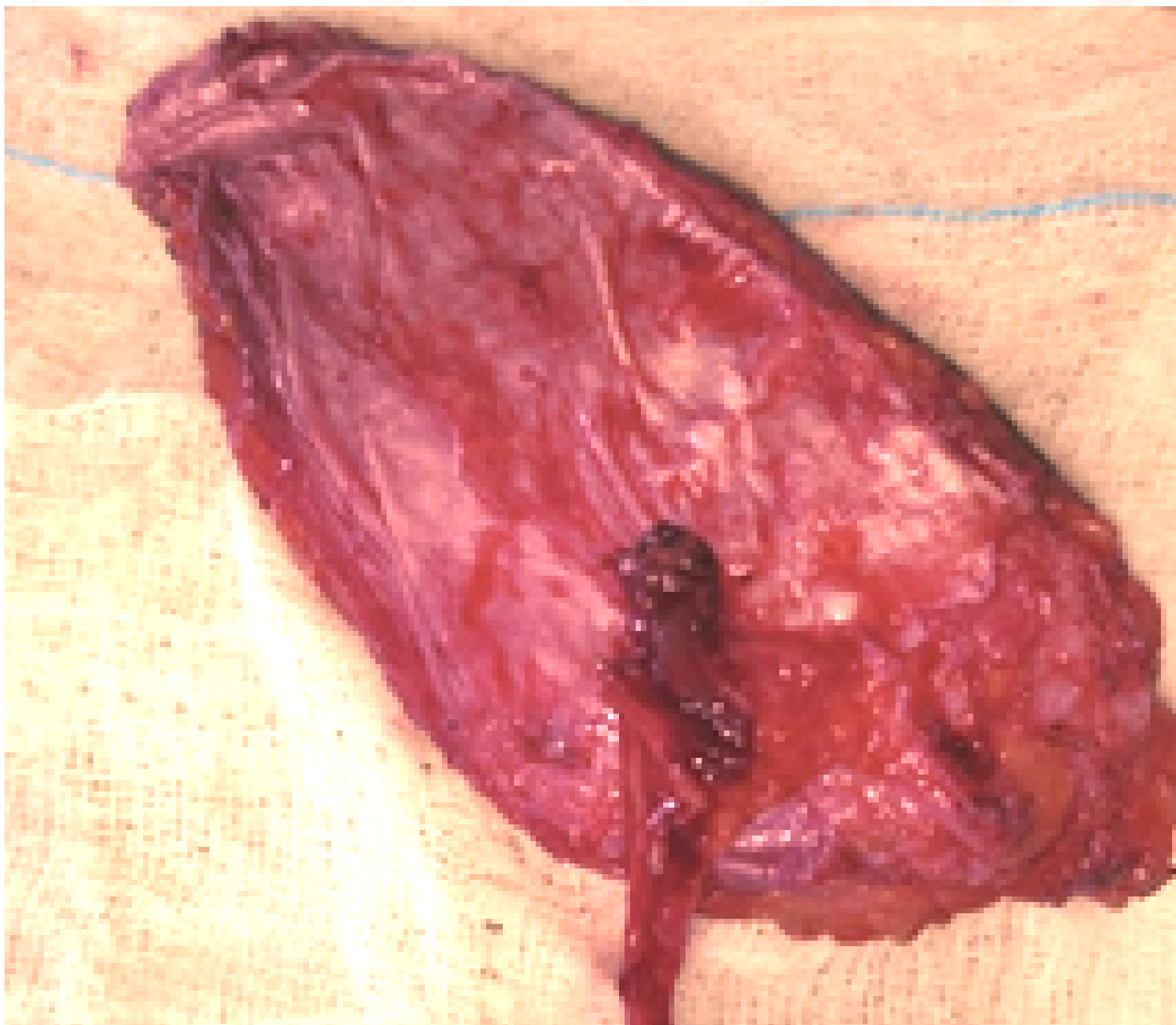


Fig 5: Single septocutaneous based ALT Flap harvest

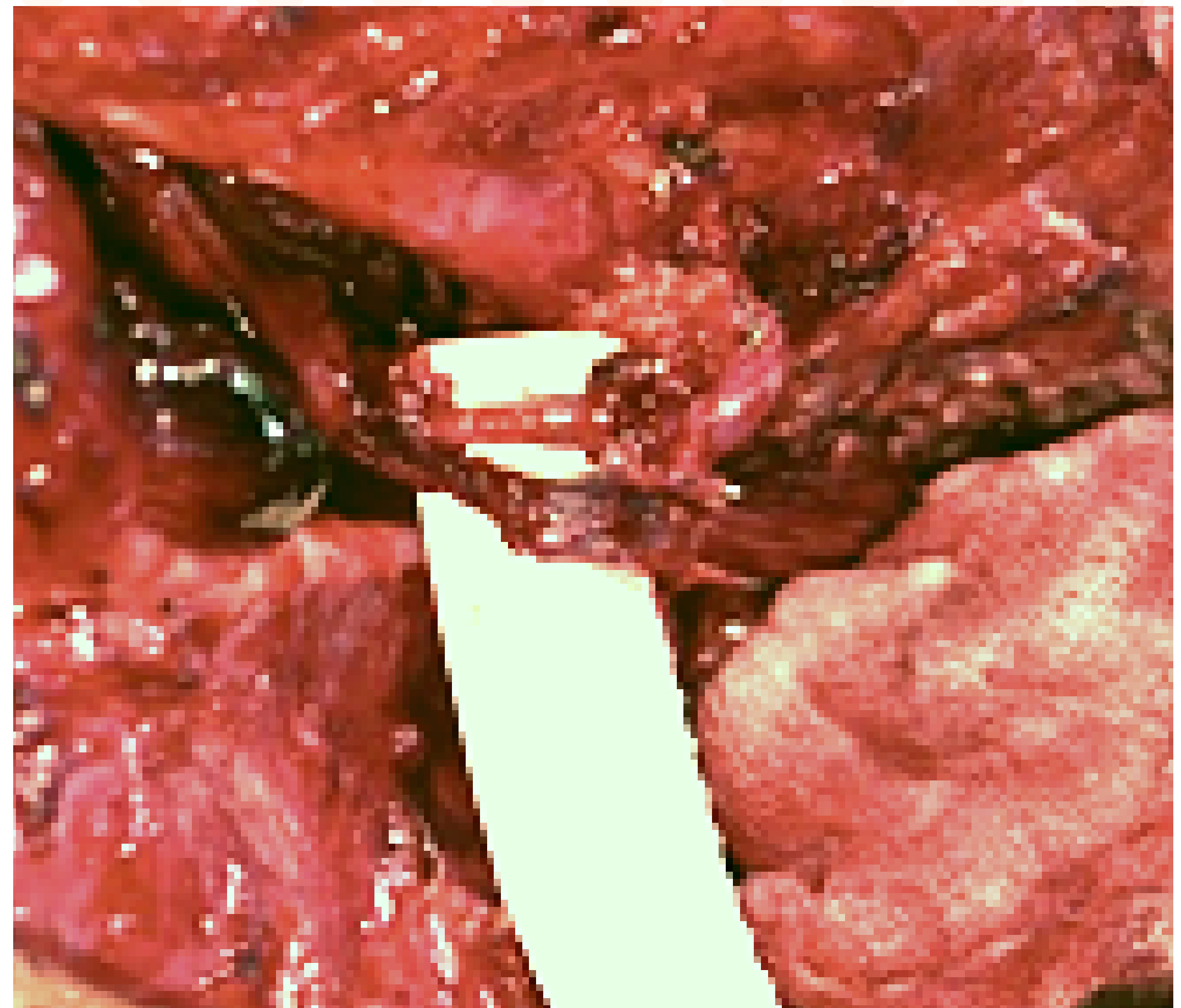



Fig 6: End to end anastomosis with facial artery and common facial vein

Hubli Super Speciality Hospital Rambhapuri Kalyana Mantap Road,
Kalyannagar Vidyanagar Hubballi – 577-001, Karnataka, India



[/hublisuperspecialityhospital/](https://www.facebook.com/hublisuperspecialityhospital/)



24X7 Call Center # 7353-040-000



www.hublisuperspecialityhospital.com



24X7 Call Center # [7353-040-000](tel:7353-040-000)



HUBLI
SUPER SPECIALITY HOSPITAL

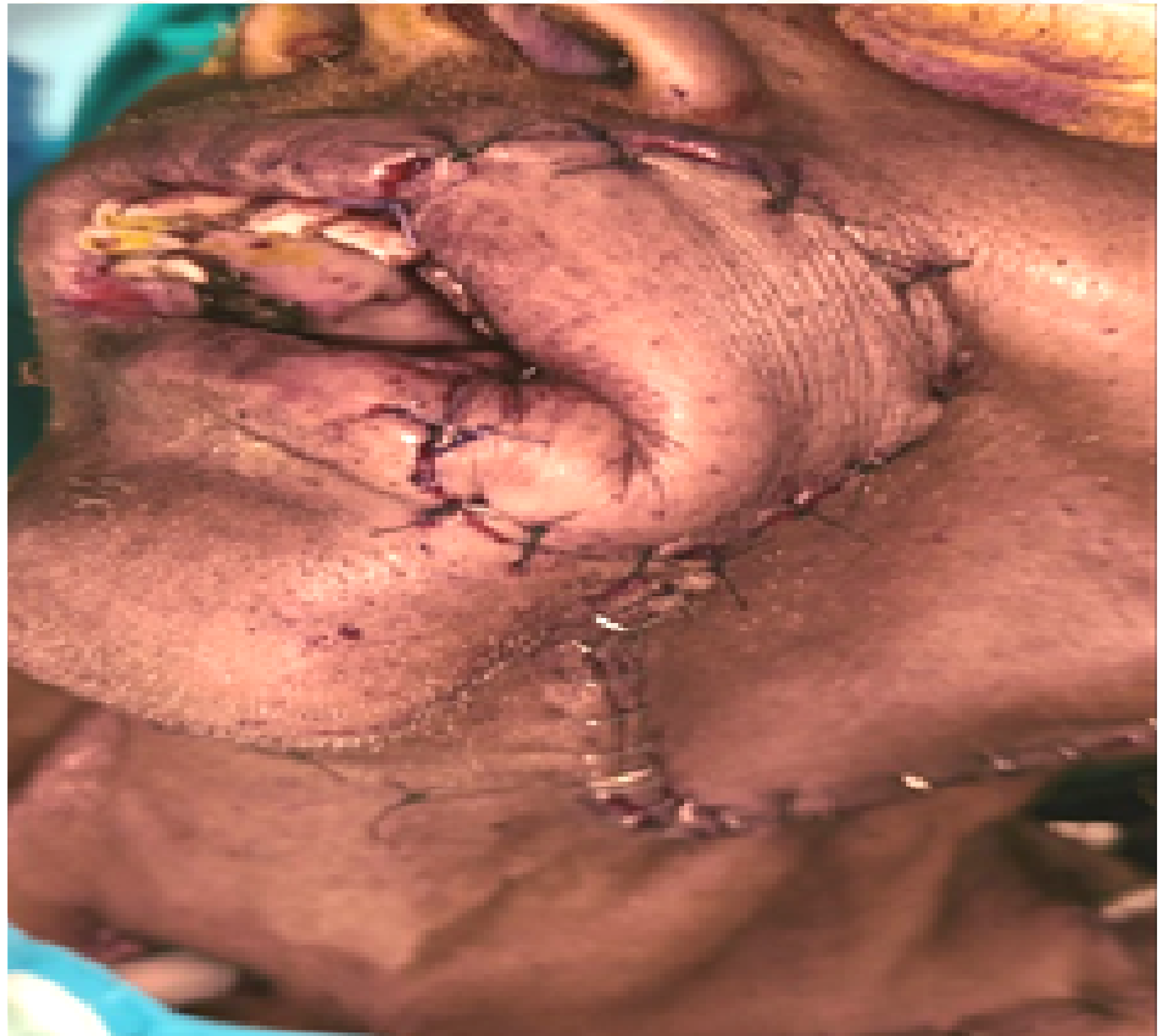
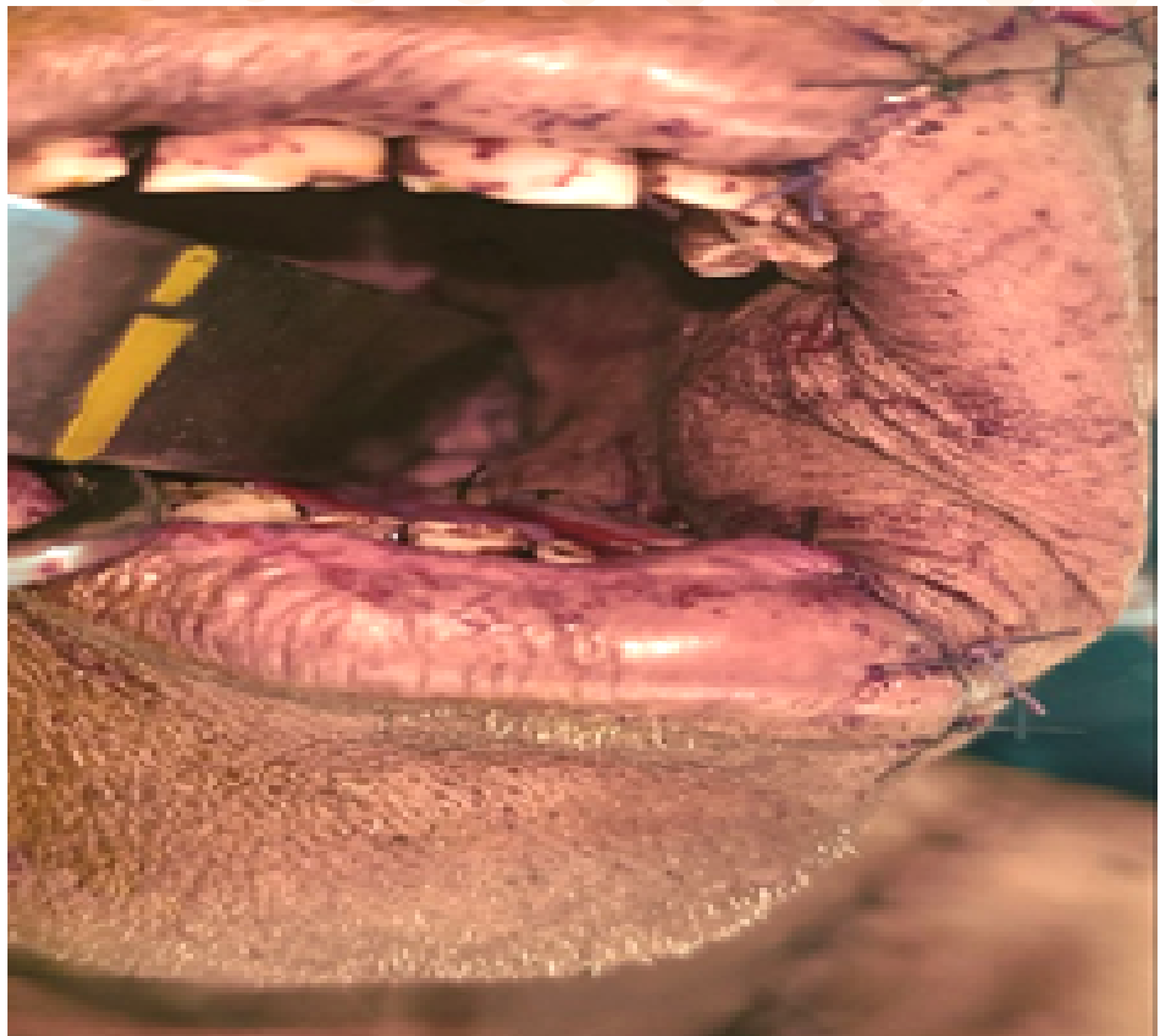



Fig 7: Reconstruction of intraoral and extra oral defect using Alt free flap



Hubli Super Speciality Hospital Rambhapuri Kalyana Mantap Road,
Kalyannagar Vidyanagar Hubballi – 577-001, Karnataka, India



[/hublisuperspecialityhospital/](https://www.facebook.com/hublisuperspecialityhospital/)



24X7 Call Center # [7353-040-000](tel:7353-040-000)



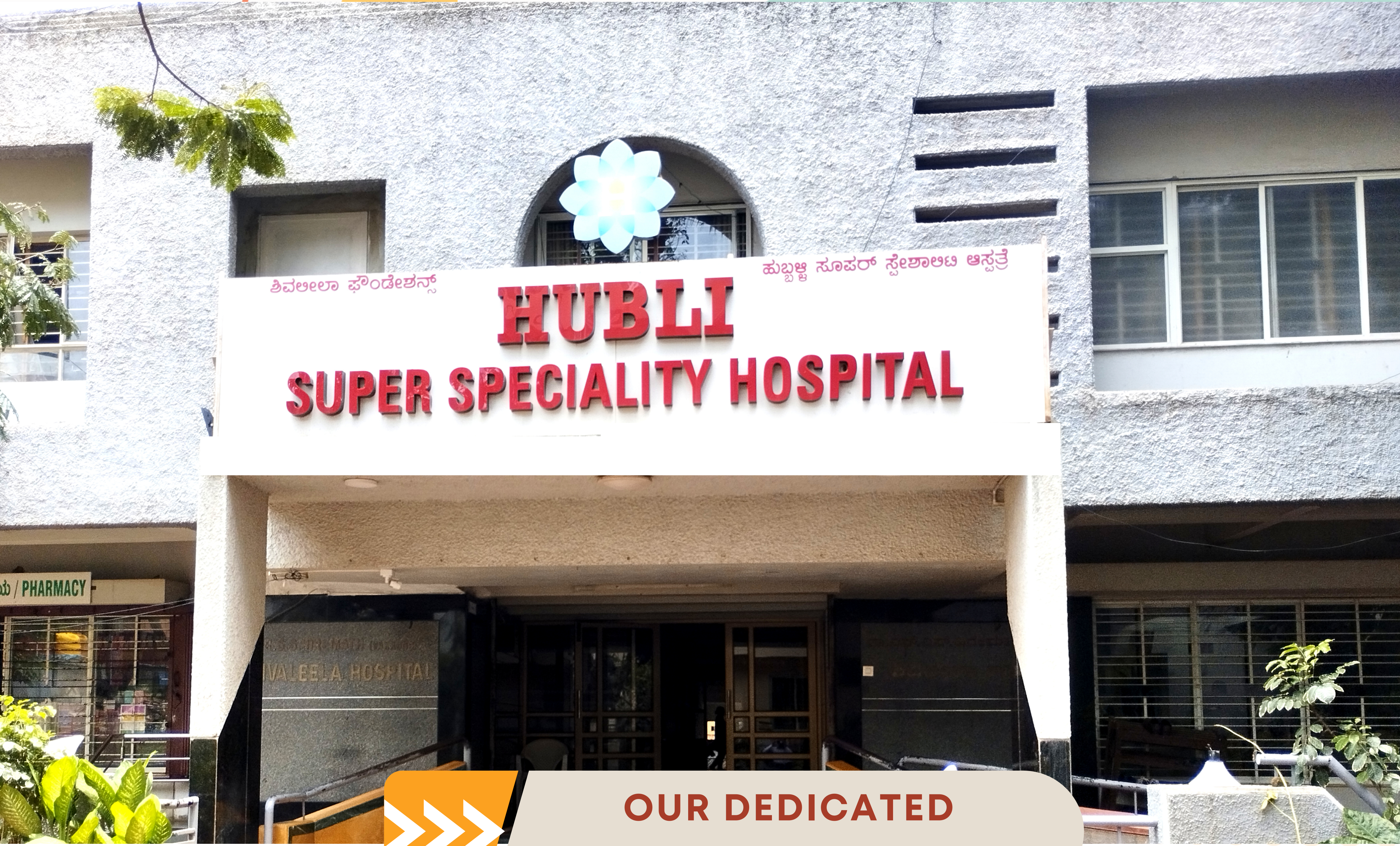www.hublisuperspecialityhospital.com



24X7 Call Center # 7353-040-000



HUBLI
SUPER SPECIALITY HOSPITAL



OUR DEDICATED DOCTORS

HEAD AND NECK ONCOLOGY

Dr.Jagadish Tubachi
Dr.Shirish Patil
Dr.Tejesh Yelamali
Dr.Vigneshwar.S

ANESTHESIOLOGY

Dr.Sairam Commi
Dr.Deepak
Dr sheetal Hiregoudar
Dr.Supriya L

MEDICAL ONCOLOGY

Dr.Kiran Kattimani

SURGICAL ONCOLOGY

Dr.Channabasappa Kori
Dr.Ajay

DENTAL SURGERY

Dr.Priyanka Yelamali

ONCOPATHOLOGY

Dr.Kanchana
Dr.Mohan Kulkarni
Dr.Snehal Reddy

PHYSIOTHERAPY

Dr.Pooja

RADIATION ONCOLOGY

Dr.Mahantesh

RADIOLOGY

Dr.Santhosh Kulgoud
Dr.Bharat Jain

Hubli Super Speciality Hospital Rambhapuri Kalyana Mantap Road,
Kalyannagar Vidyanagar Hubballi – 577-001, Karnataka, India



[/hublisuperspecialityhospital/](https://www.facebook.com/hublisuperspecialityhospital/)



24X7 Call Center # 7353-040-000



www.hublisuperspecialityhospital.com



24X7 Call Center # 7353-040-000




HUBLI
SUPER SPECIALITY HOSPITAL

RADIXACT X7 TOMOTHERAPY WORLDS BEST RADIOTHERAPY



Lesser
Treatment Time




Accurate
& Precise



Minimal
Side Effects



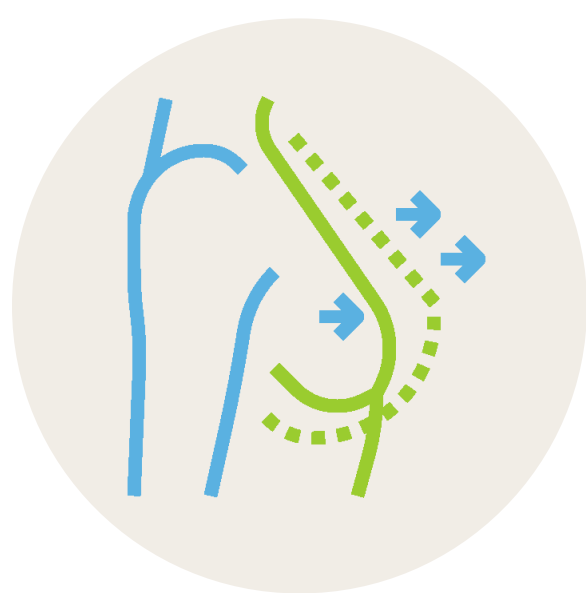Advanced
Treatment



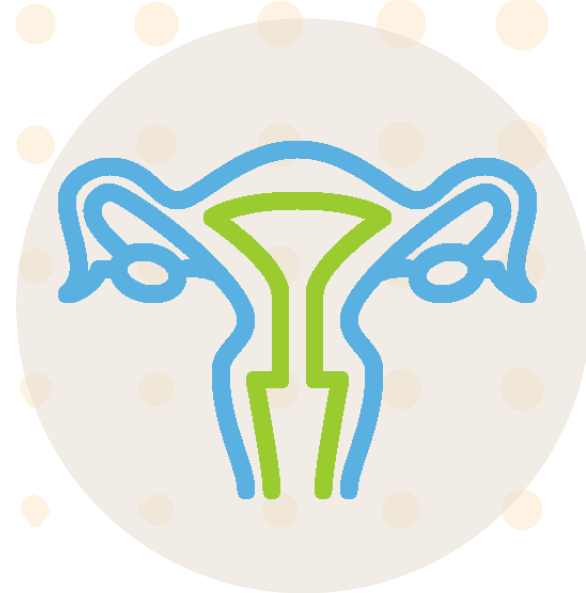
CANCERS WE TREAT



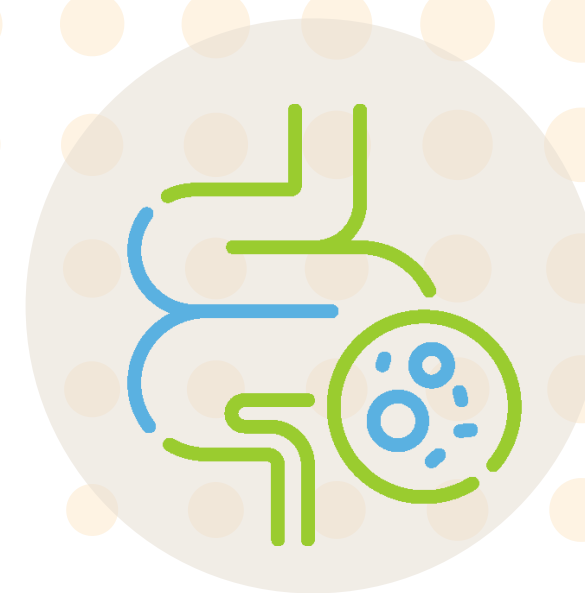
Head & Neck
Oncology



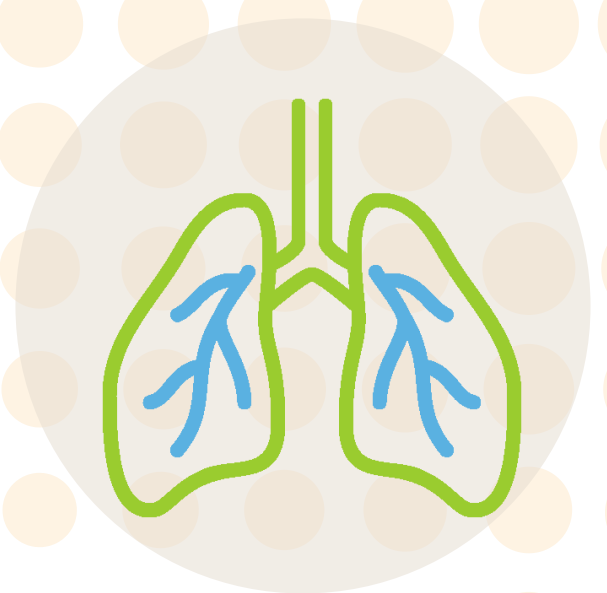Breast
Oncology



Gynaecological
Oncology



Gastrointestinal
Oncology



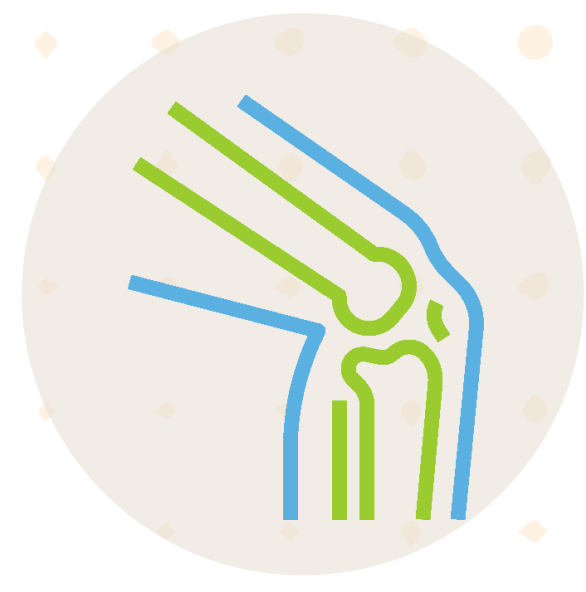Thoracic
Oncology



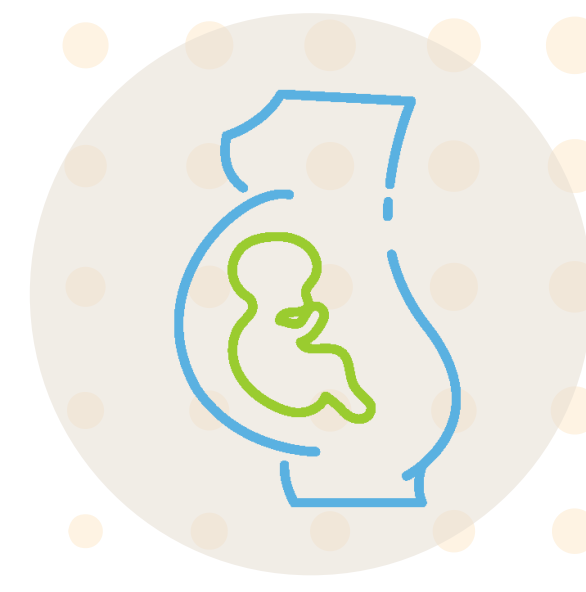Uro
Oncology



Neuro
Oncology



Bone & Soft
Tissue Oncology



Pediatrics
Oncology

Hubli Super Speciality Hospital Rambhapuri Kalyana Mantap Road,
Kalyannagar Vidyanagar Hubballi – 577-001, Karnataka, India



[/hublisuperspecialityhospital/](https://www.facebook.com/hublisuperspecialityhospital/)



24X7 Call Center # 7353-040-000